

# A place of Life and Death. Burials and human bone finds in the Iron Age settlement at Saharna Mare / "Dealul Mănăstirii": archaeological data and anthropological analysis

Mihail Băţ, Angela Simalcsik, Aurel Zanoci

## Abstract

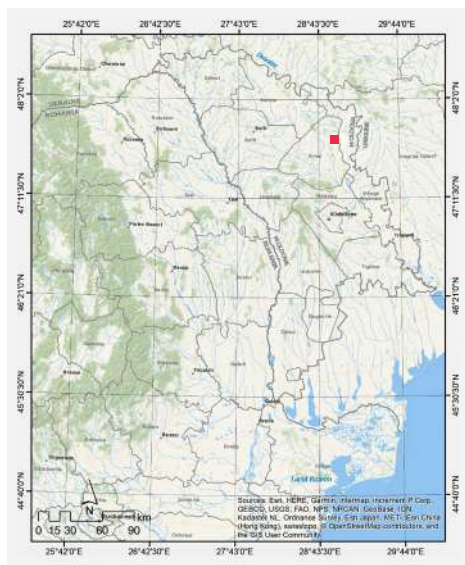Among the numerous vestiges of the Iron Age at Saharna Mare / "Dealul Mănăstirii", there are 11 finds of human remains, which are of particular interest for the interdisciplinary research of the site. In this article, we propose combining archaeological data with anthropological ones. The analyzed skeletal material comes from six types of archaeological contexts: "cultic structure", "ditch", "rampart", "grave", "dwelling", and "cultural layer" (Fig. 2; 3). In all the analyzed cases the identified osteological remains come from a single individual. In total, seven individuals were identified, one of whom is female and six are male. Regarding age distribution, most individuals fall within the age range of 30-60 years (*maturus*). One individual falls within the age range of 20-30 years (*adultus*), and another one has passed the age of 60 (*senilis*). As a result of the paleopathological analyses, a wide spectrum of dental pathologies (supragingival calculus, cavities, abscess, *antemortem* tooth loss) and bone pathologies (osteoarthritis, intervertebral disc herniation, porotic hyperostosis) were recorded. The analysis of occupational indicators showed over-demanding physical activities, spatial mobility, and horseback riding. Traces of violent death, such as cranial and postcranial fractures, have been reported in several cases. There were also identified injuries with signs of healing.

**Keywords:** Middle Dniester Region, Iron Age, settlement, fortification, burials, human bone finds, bone pathologies, dental pathologies, cutting traces, traumas, *perimortem* traumas.

## 1. Introduction

The Saharna Mare / "Dealul Mănăstirii" site is located west of the Saharna village (Rezina District, Republic of Moldova) on a promontory of quasi-trapezoidal shape with an area of about 15 ha and an altitude of about 130 m concerning the level of the Dniester River (Fig. 1). The north, east and south sides of the promontory are formed by two ravines with steep slopes, which unite on the east side in a valley called by locals "Valea Crac" (Niculiţă, Zanoci and Băţ 2016, 19).

The first archaeological investigations were carried out by G. Smirnov in 1946-1947 (Smirnov 1949, 93-96; Smirnov 1953, 19-30). In 2001-2014 and 2017-2019 the archaeological investigations were carried out by the team of the



**Fig. 1.** Saharna Mare / "Dealul Mănăstirii" on the map of the East-Carpathian area.

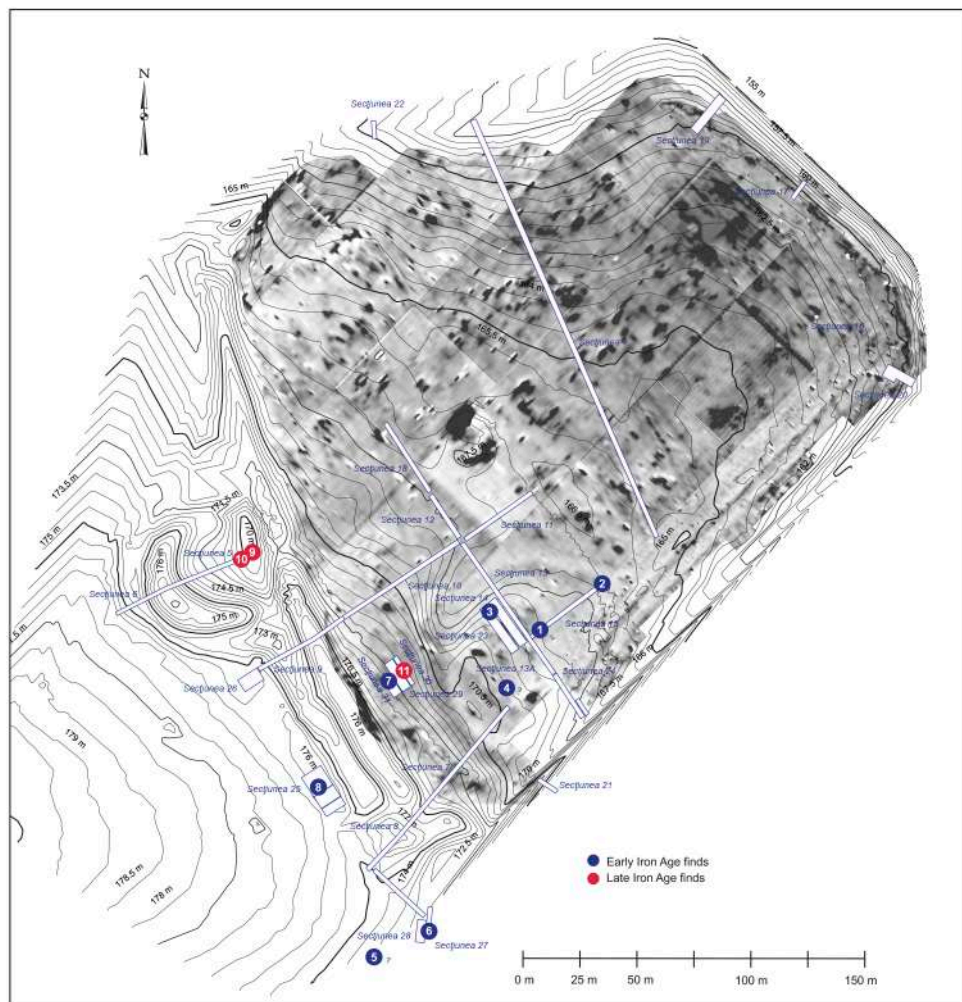
Scientific Research Laboratory "Thracology" of the Moldova State University led by Professor Ion Niculiță<sup>1</sup>. As a result, it was established that several open and fortified settlements chronologically succeeded each other on the Saharna Mare promontory between the second half of the 12<sup>th</sup> century and the end of the 3<sup>rd</sup> century BC. Thus, from the second half of the 12<sup>th</sup> century to the 11<sup>th</sup> century BC there was an open settlement, which, according to the collected artifacts, was attributed to the Holercani-Hansca culture. In the following centuries (10<sup>th</sup>-9<sup>th</sup> BC) on the promontory there was a hill-fort and a large open settlement in its immediate vicinity, which belonged

to the Cozia-Saharna culture. As for the 8<sup>th</sup>-7<sup>th</sup> centuries BC, there were found evidences in favor of the existence here of a settlement characteristic of the Basarabi-Șoldănești culture. In the 6<sup>th</sup>-3<sup>rd</sup> centuries BC on the Saharna Mare promontory there was a fortification attributed to the Thracian-Getic communities (Niculiță, Zanoci and Băț 2016, 242-248).

Among the numerous finds researched on the Saharna Mare promontory, there are a series of discoveries of human remains<sup>2</sup>, both in burial structures and in non-funerary contexts, which are of particular interest for the interdisciplinary research of the site. They are concentrated, at the moment, in the habitation layers attributed to the Cozia-Saharna, Basarabi-Șoldănești and Thraco-Getic cultures.

<sup>1</sup> The results of these investigations were reflected in several scientific articles (Niculiță, Zanoci and Arnăut 2007, 27-62; Niculiță, Zanoci and Băț 2011, 226-236; Niculiță, Zanoci and Băț 2013, 351-372; Niculiță et al. 2012, 111-167; Niculiță et al. 2013, 219-292; Niculiță et al. 2019; etc.), as well as in two monographic studies (Niculiță, Zanoci and Arnăut 2008, 51-150, fig. 40-159; Niculiță, Zanoci and Băț 2016, 19-248).

<sup>2</sup> Most of them have been published previously, but in most cases separately and not accompanied by the results of anthropological analyses (Kashuba 2000, 284; Niculiță and Nicic 2011, 225-235; Niculiță and Nicic 2013, 173-190; Niculiță et al. 2012, 141-144; Arnăut 2014, 128, fig. 40; Niculiță, Zanoci and Băț 2016, 95-98, 126-134; etc.). In some cases the human osteological material has been analyzed anthropologically (Constantinescu 2013, 211-219; Nagacevschi et al. 2019, 328-336; Simalscsik, Zanoci and Băț 2019, 62-66).



**Fig. 2.** The topographic and magnetometric map of the Saharna Mare / "Dealul Mănăstirii" settlement showing the location of human remains.

## 2. Early Iron Age (Cozia-Saharna culture)

The human bones attributed to this horizon were found both in the fortification and in the open settlement.

The fortification located on the southwestern edge of the Saharna Mare promontory, on the high bank of the Valea Crac gorge, consisted of two parts: a "citadel" of quasi-round shape in plan, with dimensions of about 74×76 m (approx. 0.50 ha), to which, on the north side, another "enclosure" of semi-oval shape was added, with the dimensions of 55×78 m (Niculiță, Zanoci and Băț 2016, Fig. 26; 29).



Feature	Cultural affiliation	Archaeological context	Sex	Age at death (years)	Age groups	Representation state
1	Early Iron Age (Cozia-Saharna)	"Cultic structure"	Female	~50	<i>maturus II-III</i> / middle-aged to old adult	parts of skeleton in partial anatomical position
2		Ditch	Male	25-30	<i>adultus</i> / young adult	fragment of mandible
3		Rampart	NDA	~50	<i>maturus II-III</i> / middle-aged to old adult	fragment of skull
4		Cultural layer	NDA	NDA	NDA	fragment of skull
5		Grave No. 1	NDA	NDA	NDA	complete skeleton in anatomical position (?)
6		Grave No. 2	Male	35-45	<i>maturus I-II</i> / middle-aged adult	complete skeleton in anatomical position
7		Grave No. 3	Male	>60	<i>senilis</i> / old adult	complete skeleton in anatomical position
8	Early Iron Age (Basarabi-Șoldănești)	Pit-house No. 1	Male (?)	~40	<i>maturus I-II</i> / middle-aged adult	skull
9	Late Iron Age	Ditch	NDA	NDA	NDA	fragment of skull
10		Ditch	Male (?)	30-40	<i>maturus I</i> / young to middle-aged adult	fragment of mandible
11		Structure No. 3/2017-2019	Male	~60	<i>maturus III-senilis</i> / old adult	isolated bones

NDA - No Data Available

**Fig. 3.** Saharna Mare / "Dealul Mănăstirii". Human remains.

As a result of the investigations, it was established that the defensive system of the "citadel" consisted of a "wall" with an adjacent ditch with a total length of about 300 m, which surrounded the enclosure. The presence and arrangement of postholes indicate that rampart, with a width of 1.00-1.20 m, was made up of two timber frames, the space between which was clogged with earth and stones. The ditch was dug in front of the rampart in all its length, having a width at the top of about 4.20-6.00 m and a depth of 1.20-1.60 m from the ancient ground surface.

The adjacent "enclosure" was delimited by a ditch, which in plan is a semi-oval. The ditch, the ends of which were joined with the "citadel" ditch, had a length of about 185 m, a width of about 3 m and a depth of about 1.00-1.40 m (Niculiță, Zanoci and Băț 2016, 45-60, fig. 26-38).

Along with the remains of some household structures and artifacts (Niculiță, Zanoci and Băț 2016, 61-154, figs. 39-102; Zanoci and Băț 2019, 7-28), human remains were also found in the "citadel" (Fig. 3).

### **Feature No. 1**

*Place of disposition.* The bones were found in the so-called "cultic structure" situated in the central part of the "citadel" (Fig. 2). The feature was discovered at a depth of 0.36 m from the modern ground surface and represents an agglomeration of irregular shape, with dimensions 1.20×1.20 m, consisting of limestone rocks (Fig. 4, 1). Under the stones, at a depth of 0.60 m, there were found several human bones in partial anatomical order (Fig. 4, 2-6) and pottery sherds specific to the Cozia-Saharna culture (Niculiță, Zanoci and Băț 2016, 95-98, fig. 62-64). At the level of human bones, at a distance of 0.55 m to the east, a hearth was found (Fig. 4, 1, 2). The association of the hearth with the human skeleton found nearby led to the hypothesis of the existence of a cultic structure in the central part of the "citadel" (Niculiță, Zanoci and Băț 2016, 97).

*Anatomical identification.* All these skeletal elements come from the same individual. The preservation state of the bones is good (Connel 2008, 9), and the representation state is partial. From the cranial segment only the mandible is present, and from the postcranial one, prevailing the bones on the right side (White and Folkens 2005) (Fig. 5, 1).

*Biological age estimation.* Dental crown wear and advanced alveolar retraction (Fig. 5, 6), along with the costal cartilages ossification and signs of joints degeneration, indicate a biological age of about 50 years – *maturus II-III* category or middle-aged to old adult (Ubelaker 1979, 82-110; Buikstra and Ubelaker 1994, 21-38; Mays 1998, 33-74; Latham and Finnegan 2010).

*Sex determination.* The features of the mandible (Fig. 5, 6) along with those of the postcranial bones (the pelvic girdle, the long bones of the limbs), determine us to attribute these elements to a female (Ubelaker 1979, 72-80; Buikstra and Ubelaker 1994, 16-21; Mays 1998, 33-74; Walrath, Turner and Bruzek 2004).

*Biomorphometric characteristics.* The mandible is gracile, with a high body, a prominent pyramidal symphysis, a short and wide vertical ramus and developed goniac muscle insertions. The humerus is platybrachic. The femur is platymeric, with slight pilastry. Tibia is eurycnemic. The skeletal stature, calcu-





1



2



3



4

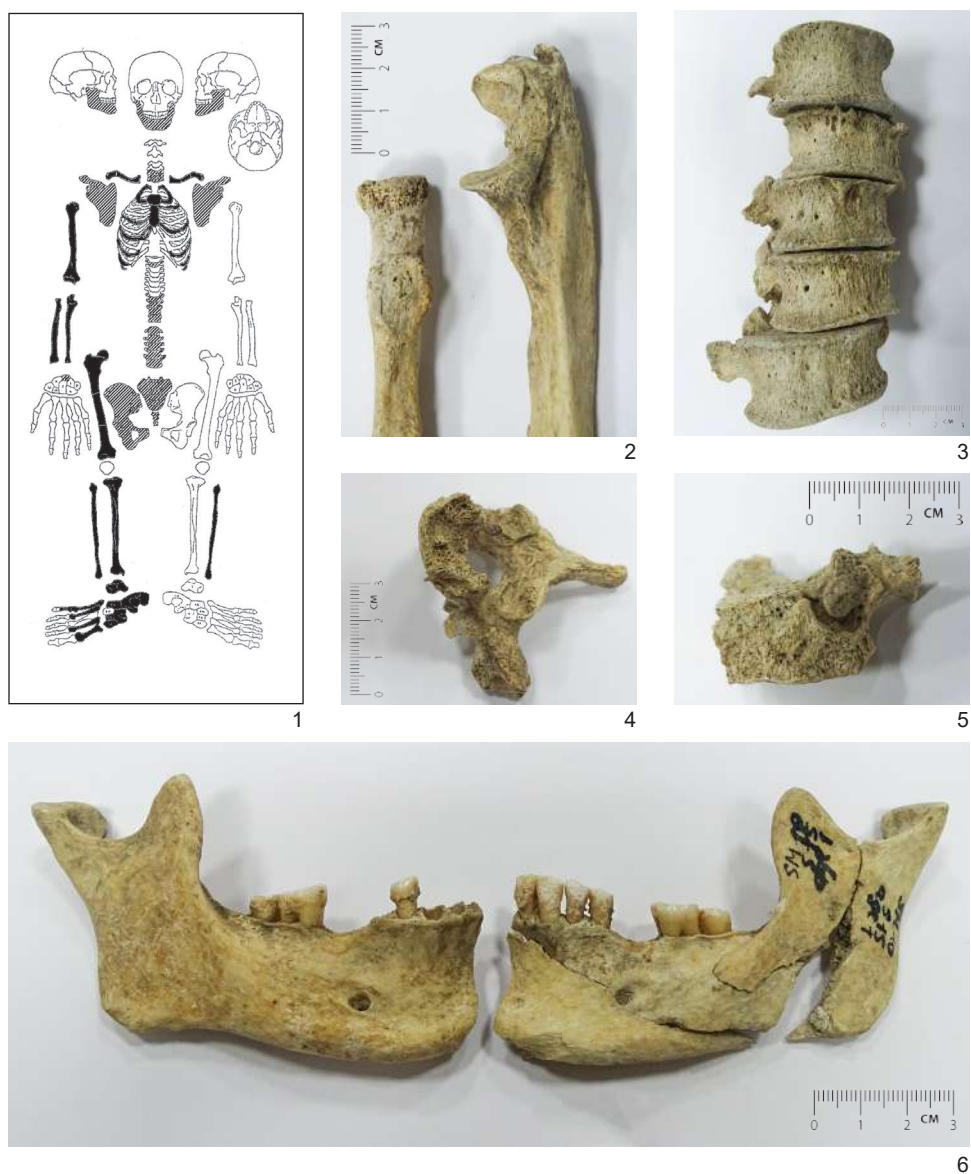


5



6

**Fig. 4.** Feature No. 1. 1-2. Cultic structure; 3-6. Human bones *in situ* (photos by Sergiu Matveev).



**Fig. 5.** Feature No. 1. 1. Representation state of the skeleton; 2. Enthesopathic changes of the radius and ulna on the right arm; 3. L1-L5 vertebrae; 4. T2 vertebra, lytic lesions; 5. C7, vertebral body, *antemortem* trauma; 6. Mandible, *perimortem* trauma.

lated according to all long bones of the right side (humerus, radius, ulna, femur, tibia, and fibula), is between 154 cm and 166 cm, values that fall into the female categories of middle to large statures.

*Non-metric/epigenetic traits.* The right  $M_3$  (Fig. 5, 6) shows microdontia. It is smaller in size than the normal ones (Ionescu 2005, 15-33).

*Dental pathologies.* The wear of the dental crowns is advanced (attrition type) (Fig. 5, 6), caused by the physiological process of chewing (Buikstra and Ubelaker 1994, 53-54). We mention tooth decay on the left P<sub>2</sub> and *antemortem* tooth loss (the left M<sub>1</sub> and the right M<sub>1</sub>) produced long before death.

*Bone pathologies.* At the postcranial level we mention osteoarthritis – degenerative joint disease, proliferative and erosive, characterized by the loss of cartilage that protects the joints surfaces. The main factors that lead to the development of osteoarthritis are age and movement, the latter being mandatory in the development of the disease (Waldron 2009, 26-71; Ortner 2003, 545-560). Osteoarthritis was identified by the presence of osteophytes on the edge of the lumbar vertebral bodies (Fig. 5, 3), on some tarsal bones (cuneiform, navicular, cuboid) and the joints of the upper right limb, especially on the elbow (Fig. 5, 2).

At the level of the T2 vertebral body, on the lower surface, a series of lytic resorptive lesions were identified (Fig. 5, 5). They are not accompanied/surrounded by reactive new tissue. The fact that the only one skeletal element presents such changes leads us to the hypothesis of tuberculosis (Mann and Hunt 2005, 15).

*Musculoskeletal stress markers.* Muscle insertions are very pronounced, especially on the humerus and femur. In some areas (ligaments and tendons) enthesophytes are developed, which are a form of response of the body to the action of musculoskeletal stress. We identified enthesopathic changes on the radial tuberosity (Fig. 5, 2), on the tuberosity of the tibia, on the calcaneus, on the rough line and the subtrochanteric area of the femur (Ortner 2003, 546-570; Waldron 2009, 26-71).

The distal end of the tibia has additional areas – squatting facets – evidence of hyperdorsiflexion (squatting, crouching) during daily activities (Prasada Rao 1966, 51-56; Tulsi and Prasada Rao 1968, 232-235).

On the proximal epiphysis of the ulna, in the insertion area of the *brachial triceps* muscle (involved in the extension of the forearm), a large spur has formed (Fig. 5, 2), which suggests the overloading of this muscle. This feature is frequently reported in the archers (Blondiaux 1994, 97-110; Molleson and Blondiaux 1994, 312-316).

On the lower side of the femur, proximally, in the immediate proximity of the gluteal tuberosity, we find the third trochanter, and on the anterior edge of the femoral neck, very close to the head-neck junction, the femoral plaque, also called the Walmsley facet. These prints sometimes indicate horse riding (Blondiaux 1994, 97-110; Molleson and Blondiaux 1994, 312-316; Radi et al. 2013, 261-262).



*Trauma.* In the left half of the mandible, both at the level of the body and the ramus, there are several fracture lines (Fig. 5, 6) that have *perimortem* characteristics, suggesting an injury/blow causing death (Aufderheide and Rodriguez-Martin 1998, 23-24).

At the level of the C7 vertebral body we identified the traces of *antemortem* trauma, with clear traces of healing (Fig. 5, 5).

*Taphonomy.* Except for the fractures produced *perimortem*, all other breaks that led to fragmentation are produced *postmortem*, most of them are old and only a few are recent (Buikstra and Ubelaker 1994, 95-106).

## **Feature No. 2**

*Place of disposition.* Another discovery of human bone remains (the mandible) was attested at the edge of the defensive ditch on the eastern part of the "citadel" (Fig. 2), at a depth of about 1.10 m from the modern ground surface.

*Anatomical identification.* The mandible – the only movable bone of the skull – is incomplete, with lacking in the right half (starting with P<sub>2</sub>) and in the region of the left condyle (White and Folkens 2005) (Fig. 6, 1).

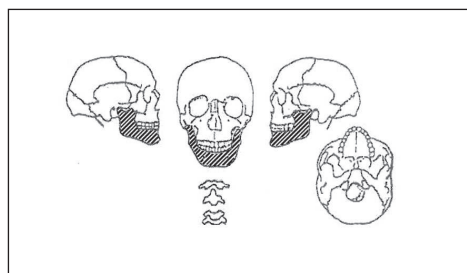
*Biological age estimation.* Dental crown wear is low and indicates the age of about 25-30 years – *adultus* category or young adult (Ubelaker 1979, 82-110; Buikstra and Ubelaker 1994, 21-38; Mays 1998, 33-74; Latham and Finnegan 2010).

*Biomorphometric characteristics and sex determination.* The morphometric features of the mandible (Fig. 6, 2-3), such as moderate robustness, pyramidal symphysis, short and wide vertical ramus, developed goniac region, projected outside of the body and branch plane, make us attribute to this incomplete mandible the male sex (Ubelaker 1979, 72-80; Buikstra and Ubelaker 1994, 16-21; Mays 1998, 33-74; Walrath, Turner and Bruzek 2004).

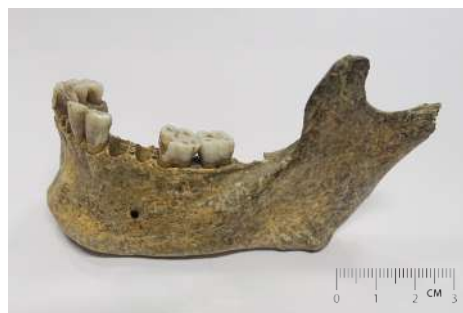*Non-metric/epigenetic traits.* The left M<sub>1</sub> has five cusps (Fig. 6, 3).

*Dental pathologies.* The wear of the dental crowns is weak (attrition type), caused by the physiological process of chewing (Buikstra and Ubelaker 1994, 53-54) (Fig. 6, 2-3). We mention a tooth loss (the left M<sub>3</sub>) produced shortly before death. On the vestibular and lingual sides (Fig. 6, 4) of the front teeth is a yellowish supragingival calculus, with low consistency and high friability, easily removable from the enamel surface (Aufderheide and Rodriguez-Martin 1998, 401-402). Alveolar retraction is slight.

*Trauma.* The fracture line of the mandibular body has *perimortem* features (Fig. 6, 4), which suggests the death-causing injury (Aufderheide and Rodriguez-Martin 1998, 23-24).



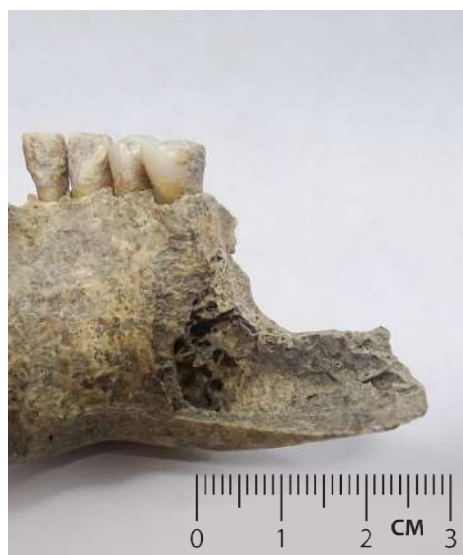1



3



2



4

**Fig. 6.** Feature No. 2. 1. Representation state of the cranial elements; 2. Mandible, frontal view; 3. Mandible, lateral view; 4. Fracture line produced *perimortem*.

*Taphonomy.* On the inner surface of the mandible, more pronounced on the lingual side of the teeth, can be noted a consistent deposits of limestone (Fig. 6, 4). In the region of the left condyle are traces from carnivorous teeth (probably) (Buikstra and Ubelaker 1994, 95-106).

### **Feature No. 3**

*Place of disposition.* Among the ruins of the rampart on the northern part of the “citadel”, at a depth of about 0.60 m from the modern ground surface, a skull fragment was discovered (Fig. 2).

*Anatomical identification.* The fragment comes from the cranial vault and includes parts of both parietals (White and Folkens 2005) (Fig. 7, 1).

### *Biomorphometric characteristics.*

The maximum dimensions of the fragment are: anterior-posterior – 108 mm, transversal – 97 mm, thickness – 8-9 mm (Fig. 7, 2-3).

*Biological age estimation.* The obliteration degree of the sagittal suture (S3-S4) (Fig. 7, 2-3) suggests the age at death of about 50 years – *maturus II-III* category or middle-aged to old adult (Ubelaker 1979, 82-110; Buikstra and Ubelaker 1994, 21-38; Mays 1998, 33-74; Latham and Finnegan 2010).

*Sex determination.* Due to lack of clear discriminatory clues, sex remains undeterminable.

*Bone pathologies.* On the external surface of the fragment has been identified the porotic hyperostosis, also called exocranial porosity or *cribra cranii* (fig. 7, 2). Its presence may suggest anemias, hypervascularization or local inflammatory processes caused by trauma, but also secondary dissemination of inflammatory processes (Ortner 2003, 136-137). Iron deficiency/sideropenic anemia is most commonly cited. In this case, porotic hyperostosis was inactive at the time of death. The severity degree is 1 – light scattered fine foramina (Stuart-Macadam 1985).

*Taphonomy.* The breaks lines of the fragment are produced *postmortem*, in ancient times, being covered with calcareous deposits strongly adherent to the bone tissue (Buikstra and Ubelaker 1994, 95-106) (Fig. 7/3).



**Fig. 7.** Feature No. 3. 1. Representation state of the cranial elements; 2. The cranial fragment seen from the exocranium; 3. The cranial fragment seen from the endocranium.



#### **Feature No. 4**

*Place of disposition.* The fourth find in this level, a fragment of a cranial vault, was made by G. Smirnov in 1946. It was attested in section no. 1 located in the southwestern sector of the hillfort, at a depth of 0.5-0.6 m (Fig. 2)<sup>3</sup>.

*Anthropological data:* According to anthropologist A. Varzari, the parietal bone fragment had a high degree of porosity, caused by a deficiency of calcium. In A. Varzari's opinion, this could be due to infectious diseases and/or frequent childbirths (Kashuba 2000, 412).

\*\*\*

In the open settlement<sup>4</sup> attributed to the Cozia-Saharna horizon, three graves have been found.

#### **Feature No. 5**

*Place of disposition.* Grave No. 1<sup>5</sup> was discovered in 1947 by G. Smirnov (Smirnov 1949, 95)<sup>6</sup>. The deceased was placed in a crouched position on his right side, at the bottom of a bell-shaped pit about 1.50 m deep (Kashuba 2000, 284; Kašuba 2008, 108; Niculiță and Nicic 2011, 225; Kašuba 2016, 101).

*Anthropological data:* no data available.

#### **Feature No. 6**

*Place of disposition.* Grave No. 2<sup>7</sup> represents a bell-shaped pit identified at a depth of 0.76-0.80 m from the modern ground level. The pit had a diameter of 1.26/1.30 m at neck, at base diameter of 1.60 m and the depth of 0.84 m. Its filling was composed of clayey chernozem mixed with stones and ash. The skeleton was placed directly on the bottom at the south extremity of the pit, on the

<sup>3</sup> The discovery is mentioned by M. Kashuba (2000, 412), who worked on the collections from G. Smirnov's excavations in 1946, as a result having found this skull fragment among the artifacts from Saharna Mare.

<sup>4</sup> The settlement, with an area of about 4 ha, is located west of the fortification, in its immediate vicinity.

<sup>5</sup> The numbering was done by us according to the order of finding.

<sup>6</sup> In the publication the location and the description of the grave are ambiguous. According to the information of G. Smirnov, it was attested in one of the three pits surveyed at the southern edge of the settlement, on the high bank of the ravine (Fig. 2). The finds from the pit with the skeleton are not clear either. G. Smirnov recalls about three cups with broken handles and several pottery sherds with incized and stamped ornament. However, it is not specified in what pits they were found (Smirnov 1949, 95). We can only assume that such fragments were discovered in the pit with the skeleton.

<sup>7</sup> Complex No. 32, Pit No. 24, according to the first publication (Niculiță and Nicic 2011, 225), found in 2010.

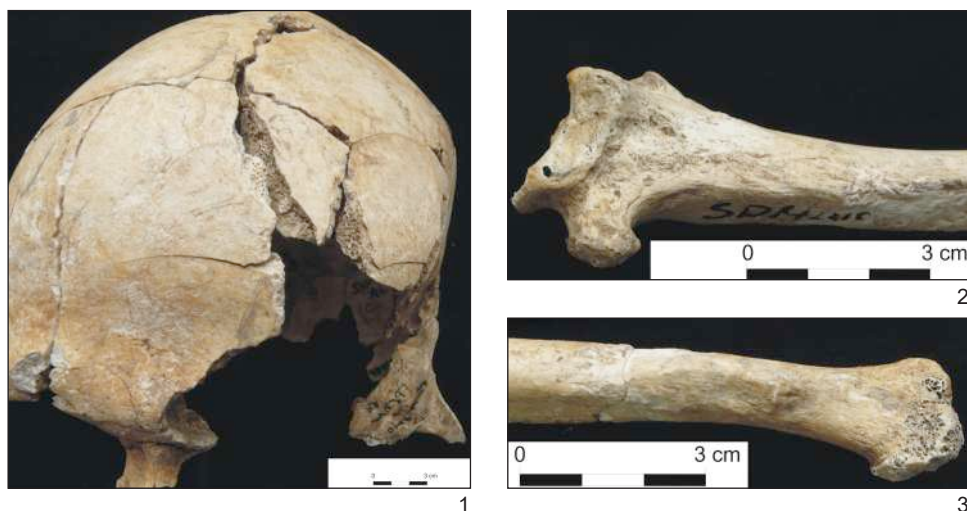



**Fig. 8.** Feature No. 6. Grave No. 2 (photos by Andrei Nicic).

right side, oriented with the head towards the west-southwest, in anatomical position, with the legs bent at the knees approximately at 90° to the north, with the right hand extended back along the body and the left one extended in front to the south (Fig. 8). Near the skull, in the south-east extremity of the pit, there was dug a niche of semi-oval shape, with the dimensions of 0.20×0.20 m. In the northeastern extremity of the pit, on the bottom, an arrangement of sherds was attested (Fig. 8). At the bottom of the pit, there were attested 12 postholes with a diameter ranging from 8 to 12 cm and a depth of up to 8.50 cm, probably left-over from a wooden superstructure (Fig. 8).

In the chest area of the skeleton, four grayish-black pieces of burnt clay with dimensions of 15×10×5 cm were found. In the region of the neck, near the dorsal vertebrae, there was attested a fragment of “altar”, which was made of clay with straw and chaff. The fragment has a height of 8 cm and a thickness of 2.30 cm and was ornamented on the edge by imprints in the form of alveoli (orifices), and on the outside by incised decoration formed by bands of zigzag lines. Imprints of twigs are preserved on the inside, the diameter of which does not exceed 2 cm. 68 fragments of pottery were collected from the grave, which according to their characteristics were attributed to the Cozia-Saharna type vessels (Niculiță and Nicic 2011, 225-228, fig. 3-5; Niculiță and Nicic 2013, 174-176, fig. 2-7; Niculiță, Zanoci and Băț 2016, 127-131, fig. 82-85).



**Fig. 9.** Feature No. 6. 1. Skull. Radiating fractures and absence of a portion of the bone. 2. Distal third of the right radius; 3. Distal third of the right ulna (after Constantinescu 2013).

The anthropological analysis of the skeleton was published in detail in 2013 (Constantinescu 2013). In the following, we will outline, in broad terms, the main characteristics of this individual.

*Biological age estimation:* 35-45 years (*maturus I-II* category or middle-aged adult).

*Sex determination.* The skeleton comes from a male individual.

*Biomorphometric characteristics.* The skeletal stature, calculated according to the maximum length of the left femur, is cca. 167 cm (over-middle male category).

*Dental pathologies:* an abscess, moderate alveolar retraction, supragingival calculus, linear enamel hypoplasia (two defects).

*Bone pathologies:* lumbar disc herniation, osteoarthritis, periosteal changes in the diaphysis of the right tibia and fibula.

*Traumas.* On the frontal are numerous fracture lines and radiant fractures (Fig. 9, 1), all without traces of healing, being produced *perimortem*, with a blunt object, probably causing death. In the distal third of the right radius a healed fracture was identified, which led to deformations of the distal epiphysis of the right ulna (Fig. 9, 2-3).

*Musculoskeletal stress markers* suggest intense physical activity throughout life.

*Taphonomy.* Many skeletal elements have been damaged in ancient times, their breaking lines being covered with a consistent layer of limestone.

### Feature No. 7

*Place of disposition.* Grave No. 3 was discovered at a depth of 1.60 m from the modern ground level (Fig. 2). The burial was made in a pit with a catacomb (Fig. 10). The burial pit was bell-shaped with a diameter of 1.80 m at neck, a diameter at base of 2.10 m and a depth of 0.80 m. The filling of the pit consists of gray soil mixed with burnt wood fragments. In the east wall of the burial pit an oval-shaped catacomb was excavated, with dimensions of 1.20×2.00 m. The entrance to the catacomb is 1.1 m wide and 0.7 m high. In the eastern part of the catacomb a niche with a depth of up to 0.5 m was excavated. The soil excavated from the catacomb is gray mixed with clay soil. When removing soil from the catacomb, a male human skeleton was discovered (Fig. 10). The deceased was laid in the catacomb in a crouched position on his right side, hands bent toward the head, palms at the chin, and legs bent at the knees. The skeleton was oriented in the north-south direction. A bone handle was placed to the right of the skull, and a fragment of a hand-shaped bowl or cup was placed above the skull of the skeleton. The surface of the vessel is polished, of a dark gray color. In the lower part, the cup has an umbo-shaped recess, and in the fragmentation area there are three ends of oblique incised lines. Also, in the catacomb there were found 31 pottery sherds and four fragments of bones, which, probably, got there after the ruin of the burial structure, at the time of the closing of the pit's grave. From the grave pit were collected: a fragment of grinding stone, two hammerstones, a whetstone, 16 pottery sherds and 121 fragments of animal bones (Niculiță et al. 2019, fig. 14-16).

At the bottom of the burial pit, eight postholes with a diameter of about 0.20-0.40 m and a depth of 0.25-0.40 m have been identified, indicating the former existence of a wooden structure (Fig. 10).



**Fig. 10.** Feature No. 7. Grave No. 3 (after Niculiță et al. 2019).



The anthropological analysis of the skeleton discovered in 2019 in the catacomb has been published in detail (Nagacevski et al. 2019, 328-333). Further we will outline, in broad terms, the main features of this individual.

*The degree of representation and the state of preservation.* The skeleton is very well represented (Fig. 11, 1). The preservation status of the analyzed skeletal components is very good.

*Biological age estimation and sex determination.* The bones come from a male individual, with the biological age at death of at least 60 years (*senilis* category or old adult).

*Biomorphometric characteristics.* The neurocranium is dolichocephalic. The occipital is tall, curved, with a slight bulge in its upper part. The forehead is wide, eurimetopic. The canine pit is deep. The zygomatics are tall and wide. The facial skeleton is high. The orbits are short and moderately wide. The nose is wide, with a tendency to rise. The jaw is narrow, relatively gracile. The horizontal facial shaping/profiling is accentuated, of the Europoid type (Fig. 11, 2-4). The postcranial bones are robust and tall, with extremely developed muscle insertions. The skeletal stature, calculated according to the length of the long bones of the limbs, is between 177 and 181 cm, values that range into the male category of large to very large statures.

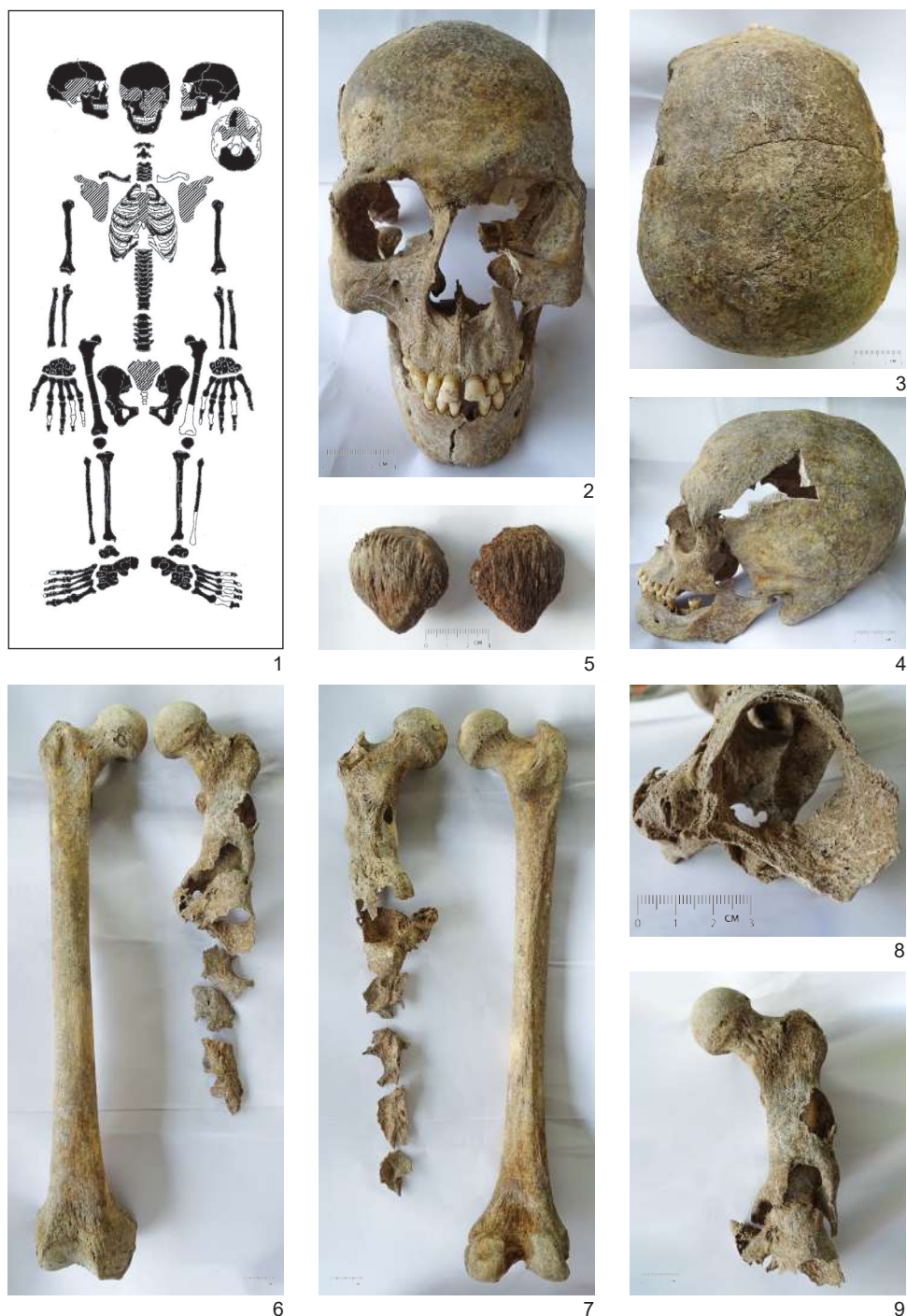
*Dental pathologies.* Dental health is precarious. We mention *antemortem* tooth loss, cavities and abscesses. The wear of the dental crowns is advanced, of mixed type (attrition and abrasion) (Fig. 11, 2, 4).

*Bone pathologies.* Almost all joint surfaces are affected by advanced degenerative osteoarthritis. The responsible factors are, first of all, the age, but also the physical activities that have overloaded the muscles and joints. The osteophytes, the enthesophytes, the corrosion, the modification of the normal articular contour are present. The manifestations of the disease are more pronounced in the pelvic girdle and the spine (especially in the lumbar segment).

Disc herniation was identified on the lower thoracic and lumbar vertebral bodies.

On the surface of the patellae (Fig. 11, 5) and at the level of the tibial diaphysis, a series of structural changes of the *periosteum* has been identified, indicating acute active inflammation at the time of death, a clear localized response of the bone system to certain pathological factors, such as trauma or infectious disease. Most likely, in this case, the aggressive and galloping extension of a microbial infection, starting from the left femur, which shows complex pathological changes (Fig. 11, 6-9), can be invoked. Only the middle (fragmentary) and proximal thirds were preserved from the left femur. We think that the bone suffered an open, multifragmentary, compound fracture, located at the





**Fig. 11.** Feature No. 7. 1. Representation state of the skeleton; 2-4. Facial, vertical, and lateral views of the skull; 5. Patellae, enthesopathic and pathological changes; 6-7. Anterior and posterior sides of the femurs; 8. Left femur, proximal third, view through the medullary canal; 9. Left femur, proximal third, pathological aggressive changes.

boundary between the median and proximal third, where bridges of the callus can be distinguished. Posttraumatically, an extremely aggressive bacterial infection (most likely, *Staphylococcus aureus* and/or *Streptococcus sp.*) consumed large portions of bone, starting from the medullary canal (Fig. 11, 8) and subsequently, crossed the bone wall, consuming the inside of the bone, which appears modified and thinned by the infectious/purulent processes (Fig. 11, 9). It was an extremely severe and very rapid inflammatory process. The subject survived a few days after the possible fracture occurred and, respectively, after the infectious process was installed; the bone had sufficient time to react so severely. The speed of this process can also be deduced from the fact that it remained localized on a single skeletal element, producing only severe periosteal reactions at the tibiae level and somewhat more superficial on the surface of the patellae. The final result was, after sufficient days of suffering, septicemia/sepsis, which led to death. So far, without further investigations (radiological, CT and histopathological examination), the final diagnosis remains questionable. We reserve the details of these results in a later work with a paleopathological profile.

*Musculoskeletal stress markers.* First of all, we mention the unintentional cranial deformation, also called the “Tumpline deformation” or “post-coronal depression” (Fig. 11, 3-4), associated with certain intense physical activities during the childhood, but also during the adult period. Other markers of daily physical activity are the pronounced muscle insertions on the clavicles and humeri, the femoral pilastry, the enthesopathic changes on the lower side of the femur, the additional femoral trochanter, the supratrochlear foramen of the humerus/humeral septal aperture.

*Taphonomy.* The breaks that led to the fragmentation of some skeletal elements are recent. No traces of oxidation or burning were identified.

### 3. Early Iron Age (Basarabi-Șoldănești culture)

#### **Feature No. 8**

*Place of disposition.* From this level<sup>8</sup> comes a human skull, without a mandible, which was found at a depth of 1.00 m from the modern ground level (Niculiță and Nicic 2011, 225, fig. 1; Niculiță and Nicic 2013, 174, fig. 1; Arnăut 2014, 128, fig. 40/3). As can be seen from the stratigraphic situation, the skull was put on its left side, oriented east-west, in a niche arranged inside the Pit-house No. 1

<sup>8</sup> The Basarabi-Șoldănești habitation is concentrated in the southwestern part of the Saharna Mare promontory and partially overlap the settlement of the previous period, of the Cozia-Saharna culture (Niculiță, Zanoci and Băț 2016, 140-154, fig. 92-102).



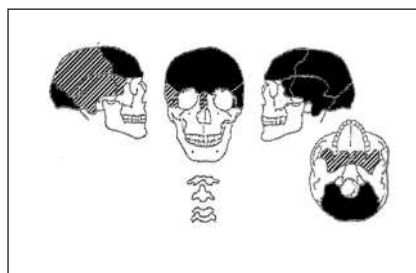
1



2



3



4

**Fig. 12.** Feature No. 8. 1. Pit-house No. 1. 2-3. Skull *in situ* (after Niculiță and Nicic 2013; Niculiță, Zanoci and Băț 2016); 4. Representation state of the skull.

(Niculiță, Nicic and Corobcean 2009, fig. 2; Niculiță, Zanoci and Băț 2016, fig. 16; 93).

The material has not been analyzed anthropologically and is currently considered lost. We will try to make an analysis, based on the images taken *in situ* (Fig. 12, 2, 3,).

*Anatomical identification.* The skull is almost complete. Part of the right parietal eminence and facial bones, including the jaw – only movable bone of the skull, are missing (Fig. 12, 4).



*Biological age estimation.* According to the pictures (Fig. 12, 3), we can analyze a generous part of the coronal suture, which shows the beginning of obliteration. We glimpse the *pars bregmatica* segment of the sagittal suture, which seems closed. The biological age of the individual from which this skull comes is about 40 years – *maturus I-II* category or middle-aged adult (Ubelaker 1979, 82-110; Buikstra and Ubelaker 1994, 21-38; Mays 1998, 33-74; Latham and Finnegan 2010).

*Sex determination.* The high degree of inclination/sloping of the forehead, the diminished frontal eminences, the prominent occipital in its upper (post-lambdoid) region, the thickened upper orbital margin, together with the developed glabellar and supraorbital relief (Fig. 12, 2-3) determine us to attribute this skull to a male (Ubelaker 1979, 72-80; Buikstra and Ubelaker 1994, 16-21; Mays 1998, 33-74; Walrath, Turner and Bruzek 2004).

#### 4. Late Iron Age

During this period, on the Saharna Mare promontory there was a fortification with a circular defensive system that surrounded an enclosure with an area of about 6 ha. The defensive elements on the west side were about 385 m long and consisted of a “wall” with an adjacent ditch. As a result of the archaeological investigations it was established that the “wall” had a width of about 5.60 m and was constructed of a wooden casing consisting of four frames filled with earth, sand, gravel and stone. The ditch had a width at the top of 15 m, at the bottom of 6 m, and a depth of about 3.20 m. Three gaps were noticed along the “wall”, one in the central part and by one on the flanks, which probably represent the former gateways. In front of these “gaps”, using the same construction technique as for the “wall” of the enclosure, bastions were built, which had its own defense ditches (Niculiță, Zanoci and Arnăut 2008, 92-97, pl. 5-6, photo 16-26).

On the north, east and south sides, which are currently quite steep, the fortification was also defended with a “wall”, the remains of which could be traced for a total length of about 650 m. On the eastern part this “wall” is winding, forming eight bastions, grouped four each on the northeast and southeast flanks. The bastions have a semi-round shape with a diameter of 9-11 m and are located at a distance of 5-6 m from each other, the distance between the groups of bastions being 34 m. A similar bastion was also attested to the north of the fortification, near the entrance gate on this side (Zanoci et al. 2019, 16-17). The archaeological investigations showed that the same building technique was used both for the construction of the “wall” and the bastions: wooden cas-



ing consisting of two timber frames filled with earth and stone. The width of the "wall" thus created varies from one portion to another, but falls within 1.1-1.6 m (Niculiță, Zanolci and Băț 2016, 156-171, fig. 103-114).

In the Thracian-Getic fortification, three findings of human bones are currently known.

### **Feature No. 9**

*Place of disposition.* It was found in the filling of the defensive ditch (Section 5/2002) on the west side of the fortification, to the right of the central entrance gate. It represents the upper part of a cranial vault with traces of an ancient fracture (Arnăut 2014, 128).

*Anthropological data:* no data available.

### **Feature No. 10**

*Place of disposition.* In the filling of the defensive ditch mentioned above, at a depth of 1.05 m, a mandible with traces of fracture on the right side was found<sup>9</sup> (Arnăut 2014, 128, fig. 40/1).

We tried to point out some features of the mandible based on the photograph published by T. Arnăut (Arnăut 2014, 370, fig. 40/1) (Fig. 13).

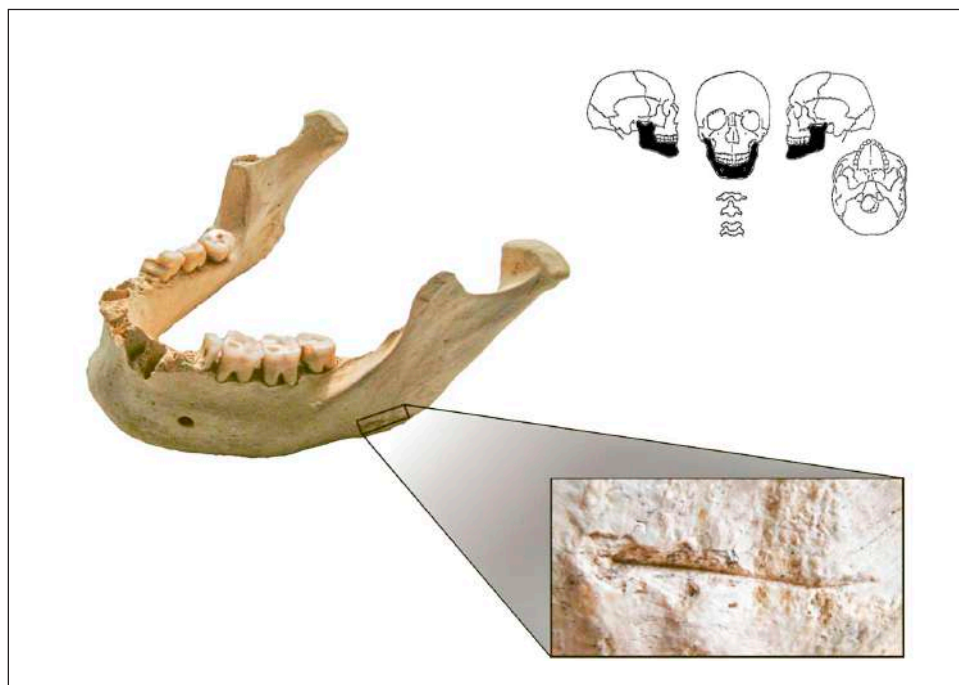
*Anatomical identification.* The mandible – the only movable bone of the skull – is almost complete (Fig. 13). Only the coronoid process on the right side is missing.

*Biological age estimation.* The molars crowns wear is attrition type, produced by the physiological phenomenon of mastication. The wear follows the classic model, M1 > M2 > M3 and indicate a biological age between 30 and 40 years – *maturus I* category or young to middle-aged adult (Ubelaker 1979, 82-110; Buikstra and Ubelaker 1994, 21-38; Mays 1998, 33-74; Latham and Finnegan 2010).

*Sex determination.* The general appearance of the mandible does not offer very clear discriminating features. The shape of the symphysis is unclear and profiling is quite attenuated, the robustness of the body seems moderate, and the left goniac region (the only one visible in the image) protrudes slightly. Perhaps only the size of the molars and the goniac angle is the elements that would cause us to support the male sex for this jaw (Ubelaker 1979, 72-80; Buikstra and Ubelaker 1994, 16-21; Mays 1998, 33-74; Walrath, Turner and Bruzek 2004).

*Non-metric/epigenetic traits.* The left M<sub>1</sub> has five cusps (Fig. 13).

<sup>9</sup> Currently the material is considered lost.



**Fig. 13.** Feature No. 10. The mandible with the location of the cut mark (after Arnăut 2014) and representation state of the skull.

*Dental pathologies.* The left  $P_1$  seems to have only a root residue, which leads us to support the presence of an advanced cavity, which consumed the crown of the tooth entirely (Fig. 13).

*Taphonomy.* The broken line of the right coronoid process has *postmortem* characteristics, as well as the cracks that led to the fragmentation of both right  $P_2$  and  $M_1$  (Fig. 13).

*Cutting traces.* At the base of the left mandibular ramus, immediately above the *gonion*, a horizontal linear lesion, parallel to the edge of the mandible body, is observed. It is a trace of cut, produced *perimortem*, with a sharp object. The location of this lesion is in the area where the *masseter* and *medial pterygoideus* muscles are inserted. We recall that these observations are made only by analyzing the photo image, which is not very clear. Even so, we dare to describe this cutting trace as narrow and quite deep, probably in the "V" shape in the section, and may be associated with the metal blades of tools or weapons (Buikstra and Ubelaker 1994, 98-99, 102). Above the line (in the cephalic direction) and below it (in the caudal direction), on the margins, the bone tissue is chipped, a feature that causes us to assume that the lesion was caused by applying a force large enough to cut its edges, but not so strong as to cause a bone fracture.



**Fig. 14.** Feature No. 11 (photos by Mihail Băț).

### **Feature No. 11**

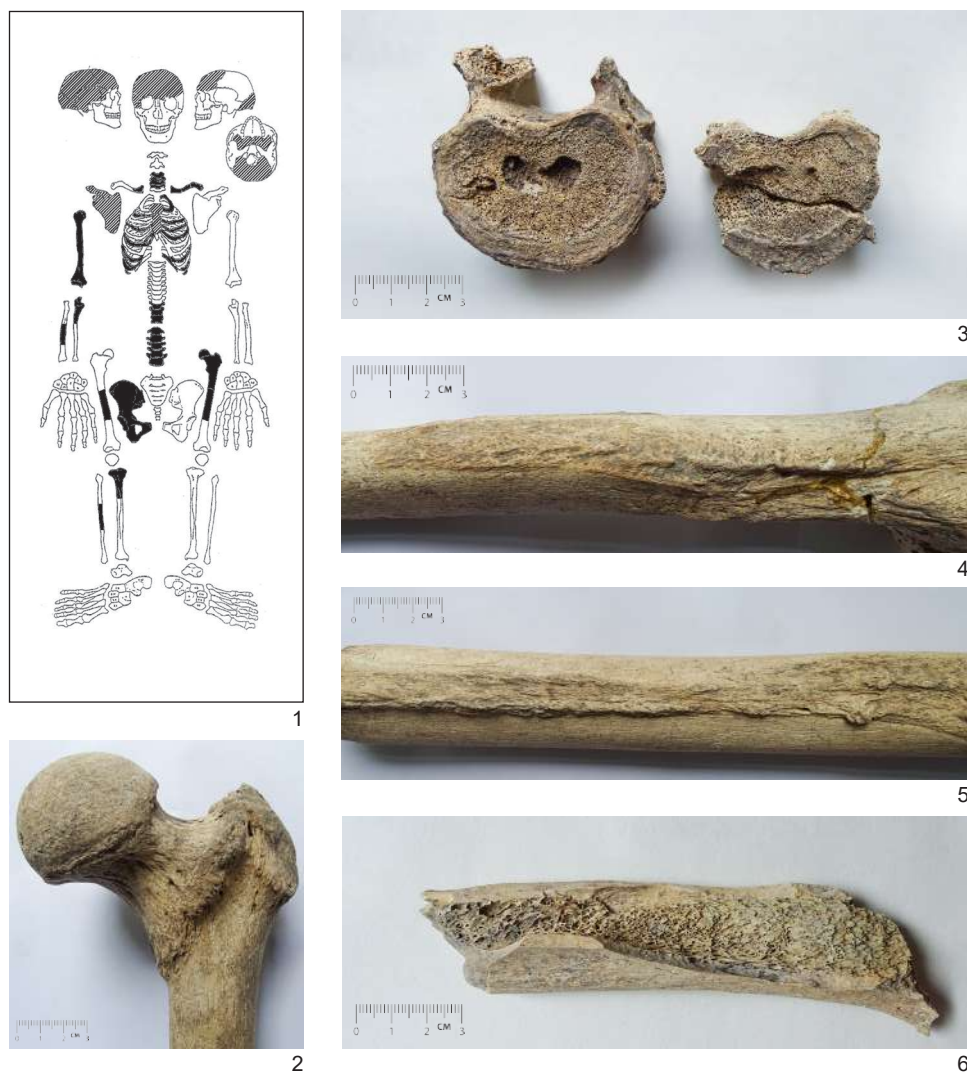
*Place of disposition.* In the eastern corner of the north room of Structure 3/2017-2019, at a depth of 0.60 m a dark gray soil stain with dimensions of 1.00×1.50 m was attested, in which several fragments of human bones were discovered (Fig. 14). The bones were scattered, not in anatomical position.

The anthropological analysis of these human remains has been published in detail (Nagacevski et al. 2019, 333-336). Further we will outline, in broad terms, the main features of this individual.

*The degree of representation and the state of preservation.* The skeleton is partially represented (Fig. 15, 1). The state of preservation of the analyzed skeletal components is satisfactory to good. All these skeletal elements come from a single individual.

*Biological age estimation and sex determination.* The bones come from a male individual, with biological age at the time of death of about 60 years (*maturus III-senilis* category or old adult).

*Biomorphometric characteristics.* The forehead appears of medium width, with weak eminences, and the occipital is quite flattened, with accentuated nuchal muscle insertions. The cranial relief is moderate. The postcranial bones are robust, with extremely pronounced muscle insertions. The skeletal stature,



**Fig. 15.** Feature No. 11. 1. Representation state of the skeleton; 2. Proximal third of the left femur, anterior view, enthesopathic changes and plaque; 3. Thoracic vertebrae T11-T12, disc herniation and marginal osteophytes; 4. Right humerus, pronounced muscle inserts and enthesopathic changes; 5. Left femur, posterior view, pronounced muscle inserts and enthesopathic changes; 6. Right femur, diaphyseal fragment, *perimortem* breaks line.

calculated according to the length of the right humerus (the only complete bone), is between 171 cm and 177 cm, values that fall into the category of large male statures.

**Bone pathologies.** On *tabula externa ossis cranii* (occipital and the right parietal) were identified porotic hyperostosis (*cribra cranii*), inactive at the time of death.



Most of the joint surfaces are affected by osteoarthritis, the first factor responsible being the age, along with movement and sustained and prolonged physical effort. All the characteristics of the disease are present: osteophytes, enthesophytes, corrosion, and deformation of the joint contour. The manifestations of the disease are more pronounced in the spine (Fig. 15, 3), but the disease also affected the coxofemoral, humeroulnar, radioulnar, glenohumeral and sternoclavicular joints.

The thoracic and lumbar vertebral bodies show intervertebral disc herniation (Fig. 15, 3). The responsible factors are degenerative diseases of the spinal disc, along with the mechanical overload of the spine.

*Trauma.* The diaphyseal fragment that comes from the right femur shows a *perimortem* fracture (around the time of death). The breaking line has no trace of healing and has all the features of an open, transversal-oblique, complete, multifragmentary fracture (Fig. 15, 6), probably produced by a mixed mechanism.

*Musculoskeletal stress markers.* The muscle insertions in the bones of the girdles and limbs (Fig. 15, 2, 4, 5) are extremely pronounced, and the enthesopathic changes suggest a series of over-demanding physical activities, such as loading or lifting weights, ground mobility, long-distance walking on uneven and rugged terrain, long-term maintenance of the body upright, equestrian activities.

*Taphonomy.* Except for the fractures produced *perimortem*, all other breaks that led to the fragmentation of the skeletal elements have occurred *postmortem*, some in ancient times. The patina of the analyzed skeletal remains is gray.

## 5. Concluding remarks

As can be seen from the distribution of the finds of human remains known so far in the Saharna Mare / "Dealul Mănăstirii" settlement, they are concentrated in the southwest part of the settlement (Fig. 2). At the present stage of the research it is still premature to talk about the existence of a space within the settlement intended for burial and deposition of human remains. This density of contexts with human remains can also be explained by the fact that the area has been the most intensively researched by archaeologists in the last two decades.

The human remains found in the settlement appear in six types of archaeological contexts: "cultic structure", "ditch", "rampart", "grave", "dwelling", and "cultural layer". The entire or partially represented skeletons come from archaeological structures and were found in anatomical order. The state of

preservation of the analyzed remains is satisfactory to good, and the state of representation is good (Features No. 1, No. 6, and No. 7). In other cases, human bones are represented, in particular, by cranial fragments (Fig. 3). One of the skulls appears to have been intentionally deposited in a niche arranged in the structure (Feature No. 8).

The position and orientation of the dead could only be established in three cases, where they lie in a crouched position with their heads in the direction of the southwest (Features No. 1 and No. 6) or north (Feature No. 7).

In all analyzed cases, the identified osteological remains originate from one individual for each feature.

In the osteological sample reported in the present study, a total of seven individuals could be identified, one of which is female and six are male. In terms of age distribution, most individuals fall within the age range of 30-60 years (*maturus*). Only one individual falls within the age range of 20-30 years (*adultus*), and another one has passed the age of 60 (*senilis*) (Fig. 3). In some cases it was not possible to determine the sex and/or estimate the age because of the lack of the osteological material and the field archaeological records (Features No. 4, No. 5 and No. 9). In another case, under conditions of very poor skeleton representation, we could determine that the fragment of neurocranium originates from an individual at the age at death of about 50 years (Feature No. 3).

The skeletal stature was estimated in four cases, being calculated by the length of the whole or restorable long bones of the limbs. The calculated value for the stature of the female individual (Feature No. 1) is between 154-166 cm and falls into the over-middle to height female category. In the case of the male individuals there are three categories: middle to over-middle – 163-172 cm (Feature No. 6), high – 171-177 cm (Feature No. 11) and high to very high – 177-181 cm (Feature No. 7).

As a result of paleopathological analyzes, a wide spectrum of dental and bone pathologies has been recorded. Thus, for dental pathologies, we note the supragingival calculus (Features No. 2 and No. 6), cavities (Features No. 7 and No. 10), abscess (Features No. 6 and No. 7) and the *antemortem* tooth loss (Features No. 1 and No. 7). In most cases, severe wear of dental crowns is observed. Some individuals (Features No. 1 and No. 2) had attrition-type tooth wear caused by the physiological process of chewing. The individual buried in the catacomb (Feature No. 7) has the tooth wear of the mixed type (attrition and abrasion). In one case, the tooth crowns are worn weak (Feature No. 2), due to the age of the buried. Besides, we can mention some cases of non-metric features, also called epigenetic, such as microdontia (Feature No. 1) and additional dental cusps (Features No. 2 and No. 10).

In the analyzed sample, a series of lesions were identified, associated with pathologies, such as tuberculosis (Features No. 1 and No. 4), osteoarthritis (Features No. 1, No. 6, No. 7 and No. 11), intervertebral disc herniation (Features No. 6, No. 7 and No. 11) and periostitis (Features No. 6 and No. 7). Porotic hyperostosis or *cribra cranii* was recorded in three cases (Features no. 3, No. 4 and No. 11). The presence of this cranial pathology may be the result of anemia or trauma.

As a result of the analysis of the occupational indicators, we can record a series of over-demanding physical activities, such as carrying loads or lifting weights, spatial mobility, walking long distances and on uneven and rough terrain, maintaining the body in an upright position, squatting, crouching, repetitive flexion-extension movements of the arms associated with the use of agricultural tools, horseback riding, etc. We also notice the unintentional "Tumpline type" cranial deformation (Feature No. 7), which is associated with carrying weights on the back supported by placing the strap over the top of the head (Nagacevschi et al. 2019, 332).

In the case of bones found in the "cult complex", there are numerous signs that prove that the skeleton belongs to a female rider and, probably, archer (Feature No. 1).

Traces of violent death were reported in several cases. Of the traumas that caused death, we notice an open multifragmentary fracture of the femur (Feature No. 11), followed by the septicemia, which led to death (Feature No. 7). Another group of perimortem traumas are skull fractures (Features No. 1, No. 2 and No. 6). It should be noted, however, that in the case of the man buried in the grave no. 2, cranial fractures and some skeleton ruptures may be due to the collapse of a wooden superstructure (Constantinescu 2013, 213).

In one case, the individual was injured at the level of the mandible, caused *perimortem* by a sharp object. The trace, probably in the form of a letter "V" in section, can be associated with the metal blades of tools or weapons (Feature No. 10).

There were also identified injuries with signs of healing (Features No. 1 and No. 6).

Many skeletal parts have been damaged in ancient times, their fractures being covered with a considerable layer of limestone (Features No. 3 and No. 6). Some of the analyzed skeletal remains show traces possibly left by the teeth of carnivorous animals (Feature No. 2).

Anthropological analysis of the skeletal material found in the Saharna Mare/"Dealul Mănăstirii" settlement aimed, as far as possible, at combining archaeological and anthropological information. Overcoming the loss of several



osteological remains, but also the publication deficiencies, the data recovered in the last years come to contribute new and relevant information useful for understanding the funerary phenomenon of deposition of the human remains inside settlements<sup>10</sup>.

## Bibliography

Ailincăi, Sorin-Cristian. 2015. *Trăind cu morții. Înmormântările în așezările de la începutul epocii fierului între Balcani, Tisa și Nistru*. Cluj-Napoca: Editura Academia Română. Centrul de Studii Transilvănene.

Arnăuț, Tudor. 2014. *Spații sacre și practici funerare din mileniul I a. Chr. în arealul carpato-balcanic*. Chișinău: Bons Offices.

Aufderheide, Arthur C. and Conrado Rodriguez-Martin. 1998. *The Cambridge Encyclopedia of Human Paleopathology*. Cambridge.

Blondiaux, Joël. 1994. "A propos de la dame d'Hochfelden et de la pratique cavaliere: discussion autour des sites fonctionnels femoraux". In *La femme pendant le Moyen Âge et l'époque moderne*, edited by Luc Buchet, 97-110. Paris: Centre National de la Recherche Scientifique.

Buikstra, Jane E. and Douglas H. Ubelaker. 1994. "Standards for Data Collection from Human Skeletal Remains" In *Arkansas Archaeological Survey Research Series*, No 44. Fayetteville.

Connell, Brian. 2008. "Preservation and archaeological data". In *Human osteology method statement*, edited by N. Powers, 9. London.

Constantinescu, Mihai. 2013. "Analiza antropologică a unui schelet din prima epocă a fierului de la Saharna (Rep. Moldova)". *Studii de Preistorie* 10: 211-219.

Ionescu, Ecaterina. 2005. *Anomaliile dentare*. București: Cartea Universitară.

Kashuba, Maya. 2000. "Ranee zhelezo v lesostepi mezhd Dnestrom i Siretom (Kultura Cozia-Saharna)". *Stratum plus* 3: 241-492.

Kašuba, Maya. 2008. "Despre depunerile de oseminte umane în așezările hallstattiene timpurii (sec. X-IX a. Chr.) cultura Saharna în regiunea Nistrului de Mijloc (spațiul nord-vest pontic)". In *Omagiu lui Gavrilă Simion la a 80-a aniversare*, edited by Sorin Cristian Ailincăi, Cristian Micu and Florian Mihai, 106-120. Constanța: Dobrogea.

<sup>10</sup> Among the studies addressed the funerary phenomenon of burials in the settlements and the manipulation of human remains in the Middle Dniester region, we can mention the following: Kašuba 2008; Kašuba 2009; Kashuba 2016; Arnăuț 2014, Ailincăi 2015.



Kašuba, M. 2009. "Die Bestattungen der Saharna-Kultur. Ein Beitrag zum frühhallstattzeitlichen Bestattungsrits im Mitteldnestrgebiet, Nordwestpontikum. In *Der Schwarzmeerraum vom Äneolithikum bis in die Früheisenzeit (5000-500 v. Chr.). Kommunikationsebenen zwischen Kaukasien und Karpaten* edited by Joni Apakidze, Blagoe Govedarica and Bernard Hänsel. Prähistorische Archäologie in Südosteuropa, Band 25, 160-189. Rahden/Westf: Verlag Marie Leidorf.

Kashuba, Maya. 2016. "Pogrebeniia na poseleniakh v rannegalshtatskoi kulture Saharna Vostochnogo Prikarpatia: norma ili iskluchenie?" In *Drevnie nekropoli i poseleniia: postpogrebalnye ritualy, simvolicheskie zakhoroneniia i ogrableniia*. Trudy IIMK RAN, t. 46, 96-112. Sankt Petersburg: Невская книжная типография.

Latham, Krista E., and Michael Finnegan (eds.). 2010. *Age Estimation of the Human Skeleton*. Illinois: Springfield.

Mays, Simon. 1998. *The archaeology of human bones*. London-New York: Routledge.

Mann, Robert W. and David R. Hunt. 2005. *Photographic Regional Atlas of Bone Disease: A Guide to Pathologic and Normal Variation in the Human Skeleton*. Illinois: Springfield.

Molleson, Theya and Joël Blondiaux. 1994. "Riders' bones from Kish". *Cambridge Archaeological Journal* 4: 312-316.

Ortner, Donald J. 2003. *Identification of Pathological Conditions in Human Skeletal Remains*. Oxford: Academic Press.

Prasada Rao, P.D. 1966. "Squatting facets on the talus and tibia in Australian Aborigines". *Archaeology and Physical Anthropology in Oceania* 1/1: 51-56.

Radi, Nico, Valentina Mariotti, Alessandro Riga, Stefania Zampetti, Chiara Villa and Maria Giovanna Belcastro. 2013. "Variation of the Anterior Aspect of the Femoral Head-Neck Junction in a Modern Human Identified Skeletal Collection". *American Journal of Physical Anthropology* 152: 261-272.

Nagacevschi, Tatiana, Angela Simalcsik, Vitalie Sochircă and Margareta Simina Stanc. 2019. „Cercetări interdisciplinare la situl Saharna Mare / „Dealul Mănăstirii”, raionul Rezina (2017-2019)”. *Tyragetia s.n.* XIII/1: 323-327.

Niculîță, Ion, Andrei Nicic and Andrei Corobcean. 2009. "Rezultatele investigațiilor arheologice la așezarea civilă Saharna-„Dealul Mănăstirii” (campania 2008). *Tyragetia s.n.* III/1: 193-225.

Niculîță, Ion and Andrei Nicic. 2011. "Practici funerare în situl din prima epocă a fierului de la Saharna-Dealul Mănăstirii". *Tyragetia s.n.* V/1: 225-235.

Niculîță, Ion and Andrei Nicic. 2013. "Pratique funéraires dans le site de la première époque du fer de Saharna-Dealul Mănăstirii". *Mousaios* XVIII: 173-190.



Niculită, Ion, Aurel Zanoci and Tudor Arnăuț. 2007. „Sistemul defensiv al cetății din epoca fierului – Saharna Mare”. *Tyrageția s.n.* I/1: 27-62.

Niculită, Ion, Aurel Zanoci and Tudor Arnăuț. 2008. *Habitatul din mileniul I a. Chr. în regiunea Nistrului Mijlociu (siturile din zona Saharna)*. Chișinău: Bons Offices.

Niculită, Ion, Aurel Zanoci and Mihail Băț. 2011. “Die frühhallstattzeitliche Befestigung von Saharna, Rajon Rezina, Republik Moldova”. In *Der Schwarzmeerraum von Äneolithikum bis in die Früheisenzeit (5000-500 v. Chr.)*, edited by Eugen Sava, Blagoe Govedarica, and Bernard Hänsel. *Prähistorische Archäologie in Südosteuropa*, Band 27, 226-236. Rahden/Westf: Verlag Marie Leidorf.

Niculită, Ion, Aurel Zanoci, Mihail Băț and Sergiu Matveev. 2012. “Investigațiile arheologice la situl Saharna Mare (2009-2011) (I)”. *Tyrageția s.n.* VI/1: 111-167.

Niculită, Ion, Aurel Zanoci, Mihail Băț and Sergiu Matveev. 2013. “Investigațiile arheologice la situl Saharna Mare (2009-2012) (II)”. *Tyrageția s.n.* VII/1: 219-292.

Niculită, Ion, Aurel Zanoci and Mihail Băț. 2013. “Siturile de pe interfluviul Saharna Mare (sfârșitul sec. XII - sec. III a. Chr.)”. In *Din preistoria Dunării de Jos. 50 de ani de la începutul cercetărilor arheologice la Babadag (1962-2012)*. Actele conferinței “Lower Danube Prehistory. 50 years of excavations at Babadag” (Tulcea, 20-22 septembrie 2012), edited by Sorin-Cristian Ailincăi, Alexandra Țârlea and Cristian Micu, 351-372. Brăila: Istros.

Niculită, Ion, Aurel Zanoci and Mihail Băț. 2016. *Evoluția habitatului din microzona Saharna în epoca fierului*. Chișinău: Cartdidact.

Niculită, Ion, Aurel Zanoci, Mihail Băț and Victor Dulger. 2019. “Investigațiile arheologice la situl Saharna Mare / „Dealul Mănăstirii”, raionul Rezina (2017-2019)”. *Tyrageția s.n.* XIII/1: 253-322.

Simalcsik, Angela, Aurel Zanoci, and Mihail Băț. 2019. “Oseminte umane descoperite în citadela hallstattiană timpurie de la Saharna Mare - Dealul Mănăstirii”. In *Colocviul Național „Fortificații și sisteme de fortificare în spațiul estcarpatic, din neolitic până în Evul Mediu”* (21-22 septembrie, Muzeul de Istorie și Etnografie Târgu Neamț). Program și rezumate, edited by Vasile Diaconu, and Ciprian-Dorin Nicola, 62-66. Piatra-Neamț: Editura Constantin Matasă.

Smirnov, Georgii. 1949. “Skifskoe gorodishche i selishche «Bol'shaia Saharna»”. *Kratkie soobshchenia Instituta Istorii Materialnoi Kultury XXVI*: 93-96.

Smirnov, Georgii. 1953. *Otchetnye materialy po arkheologicheskim issledovaniyam Moldavii za 946-1953 gody*. Kishinev. Arhiva MNIM, inv. nr. 507.

Stuart-Macadam, P. 1985. "Porotic hyperostosis: Representative of a childhood condition". *American Journal of Physical Anthropology* 66/4: 391-398.

Tulsi, R.S. and P.D. Prasada Rao. 1968. "Ilio-tibial facet of the tibia in the Australian Aborigine". *Archaeology and Physical Anthropology in Oceania* 3: 232-235.

Ubelaker, Douglas H. 1979. *Human Skeletal Remains: Excavation, Analysis and Interpretation*. Washington D.C.: Taraxacum.

Waldron, Tony. 2009. *Palaeopathology*. Cambridge, New York: Cambridge University Press.

Walrath, Dana E., Paul Turner and Jaroslav Bruzek. 2004. "Reliability test of the visual assessment of cranial traits for sex determination". *American Journal of Physical Anthropology* 125: 132-137.

White, Tim D. and Pieter A. Folkens. 2005. *The Human Bone Manual*. Amsterdam, Boston: Elsevier Academic.

Zanoci, Aurel, Ion Niculiță, Mihail Băț and Victor Dulgher. 2019. "Noi elemente defensive, descoperite recent la fortificația traco-getică Saharna Mare". In *Conferința științifică „Istorie. Arheologie. Muzeologie” a Muzeului Național de Istorie a Moldovei* (17-18 octombrie 2019, Chișinău). Rezumatele comunicărilor, 16-17. Chișinău.

Zanoci Aurel and Mihail Băț. 2019. "Structuri gospodărești din incinta fortificației hallstattiene timpurii Saharna Mare/„Dealul Mănăstirii” / Household structures from the enclosure of the Early Iron Age hillfort Saharna Mare/„Dealul Mănăstirii”. In *Structuri arheologice din așezările epocii fierului în spațiul tiso-nistean. Materialele colloquium-ului de vară de la Saharna* (Saharna, 12-15 iulie 2018) / *Archeological structures at the Iron Age settlements in the Tisza-Dniester region. Proceedings of the Saharna Summer Colloquium* (Saharna, July 12nd-15th, 2018) edited by Aurel Zanoci, Mihail Băț, Alexandra Țârlea and Sorin-Cristian Ailincăi, 7-28, Cluj-Napoca: Editura Mega.

## **Un loc al vieții și al morții. Învmormântări și descoperiri de oseminte umane în așezarea din epoca fierului de la Saharna Mare / "Dealul Mănăstirii": date arheologice și analize antropologice**

### **Rezumat**

Printre numeroasele vestigii atribuite epocii fierului de la Saharna Mare / "Dealul Mănăstirii" se evidențiază 11 descoperiri de oseminte umane, care prezintă un interes deosebit pentru cercetarea interdisciplinară a sitului. În articolul de față ne-am propus reunirea informațiilor arheologice cu cele antropologice.



Materialul scheletic analizat provine din șase tipuri de contexte arheologice: „complex de cult”, „șanț”, „palisadă”, „mormânt”, „locuință” și „strat cultural” (Fig. 2; 3). În toate cazurile analizate resturile osteologice identificate provin de la câte un singur individ. În total, au putut fi identificați șapte indivizi, din care unul este de sex feminin și șase sunt de sex masculin. Din punct de vedere al repartiției pe vârste, majoritatea indivizilor se încadrează în intervalul de vârstă 30-60 ani (*maturus*). Un singur individ se încadrează în intervalul de vârstă 20-30 ani (*adultus*), iar altul a trecut de vârsta de 60 ani (*senilis*). Ca urmare a analizelor paleopatologice, a fost înregistrat un spectru larg de patologii dentare (tartrul supragingival, caria, abcestul, căderile dentare antemortem) și osoase (osteoritra, hernia intervertebrală, hiperostoza porotică). S-a urmărit și indentificarea markerilor stresului ocupațional, asociați cu activitățile fizice suprasolicitante, mobilitatea terestră, activitățile ecvestre etc. La o serie de indivizi au fost atestate urme de moarte violentă, precum fracturile craniene și postcraniene. Au fost identificate și traumatisme cu urme de vindecare.

**Cuvinte cheie:** regiunea Nistrului Mijlociu, epoca fierului, așezare, fortificație, înmormântări, resturi osteologice umane, boli osoase, boli dentare, urme de tăiere, traumatisme, traumatisme *perimortem*.

**Mihail Băț,**

Moldova State University, Chisinau, Republic of Moldova.

E-mail: mb\_usm@yahoo.com

**Angela Simalcsik,**

“Olga Necrasov” Centre for Anthropological Research, Iași, Romania/

Institute of Bioarchaeological and Etnocultural Research, Republic of Moldova.

E-mail: angellisimal@gmail.com

**Aurel Zanoci,**

Moldova State University, Chisinau, Republic of Moldova.

E-mail: azanoci@gmail.com